

A rare case of pancreatic Arteriovenous Malformation: A case report with review of literature

Dr. Rozil Gandhi¹, Dr. Aditi Gandhi¹, Dr. Yogesh Harwani¹, Dr. Nisarg Thakkar¹, Dr. Vikas Kagathara², Dr. Juhi Porecha³

¹ Sushrut hospital, Mahalaxmi cross road, Ramvihar society, Paldi, Ahmedabad, Gujarat, India

² Assistant professor, Shri MP shah medical college, Jamnagar, Gujarat, India

³ Resident, Shri MP shah medical college, Jamnagar, Gujarat, India

DOI: <https://doi.org/10.66856/ijrr.2026.8.1.7027>

Abstract

Intraabdominal arteriovenous malformations [AVMs] are rare and mostly asymptomatic. Among these Pancreatic AVM is a very rare entity [accounting for only 0.9 % of intra-abdominal AVMs] with less than 100 cases are found in the literature [1]. Most of the patients remain asymptomatic or may present with complain of pain in abdomen, gastro-intestinal bleeding in form of melena or portal hypertension. Our case describes a 57-year-old man with complain of upper abdominal pain and melena. Upper gastro-intestinal [GI] endoscopy shows oozing of blood near ampulla vater. We confirmed the diagnosis of pancreatic AVM on contrast enhanced computed tomography [CECT] abdomen. We described the diagnosis of pancreatic AVM by CECT abdomen with it's treatment including embolization of the feeding arteries. Bleeding completely stops after embolization.

Keywords: Pancreatic arteriovenous malformations [AVMs] Embolization

Introduction

Pancreatic arteriovenous malformations [AVMs] is described as abnormal vascular network between feeding arteries and draining veins in the pancreatic region. AVMs can occur in any part of the body.

Pancreatic arteriovenous malformations [AVMs] represent rare vascular anomalies, which are classified as congenital or acquired.

Congenital AVMs are hypothesized to originate from persistent embryonic vascular networks. It can be an isolated finding or it can be associated with Osler-Weber-Rendu disease, an autosomal dominant syndrome, in 10-30% of patients [2].

Acquired AVMs are frequently associated with trauma, neoplastic processes, chronic inflammation or as a complication of pancreatic transplantation.

AVM of the pancreas induces the blood flow of the regional arteries into the portal venous system without passing the normal capillary vessels, resulting in portal hypertension, causing gastrointestinal bleeding and/or rupture of oesophageal varices [3]. however, the reasonable diagnostic procedures have not yet been established. Haemorrhagic events may manifest through direct bleeding into the pancreatic duct, intestinal haemorrhage, or hyperkinetic portal hypertension driven by aberrant arterio-venous shunting. Furthermore, altered hemodynamic can induce ischemia, potentially contributing to the development of duodenal ulcers or duodenitis. The pathological shunting of arterial blood into the portal venous system exacerbates tissue ischemia and elevates portal venous pressure. Once portal hypertension is established, therapeutic interventions such as surgical resection or trans arterial embolization often fail to restore normal portal pressure, conferring a poor prognosis. Diagnostic modalities, including color doppler ultrasonography and computed tomography, are essential for identifying these vascular anomalies, enabling early intervention and optimized clinical management.

The purpose of this case review is to highlight the clinical presentation, diagnostic challenges, and management of pancreatic arteriovenous malformation [AVM], a rare vascular anomaly. By reviewing current literature and analysing reported cases, including our own, this review aims to improve awareness of the condition's pathophysiology, emphasize the importance of early diagnosis, and evaluate the treatment strategies in improving patient outcomes.

Case Presentation

- **Patient Information:** A 57-year-old male patient, alcoholic.
- **Clinical Findings:** Abdominal pain since 3 months associated with melena since 3 days.
- **Diagnostic Assessment:** Computed tomography, Digital subtraction angiography – The AVM involving head of pancreas was found which derive arterial blood supply from gastroduodenal and inferior pancreaticoduodenal artery, and drained into one of the tributaries of the portal vein.
- **Therapeutic Intervention:** Transcatheter endovascular embolization of gastroduodenal artery and inferior pancreatico-duodenal artery.
- **Follow-up and Outcomes:** Short- and long-term outcomes

Image 1. and 2. (Contrast enhanced CT scan abdomen:- Vascular channels around the pancreas in the head region – pancreatic A-V malformation – Red arrows)

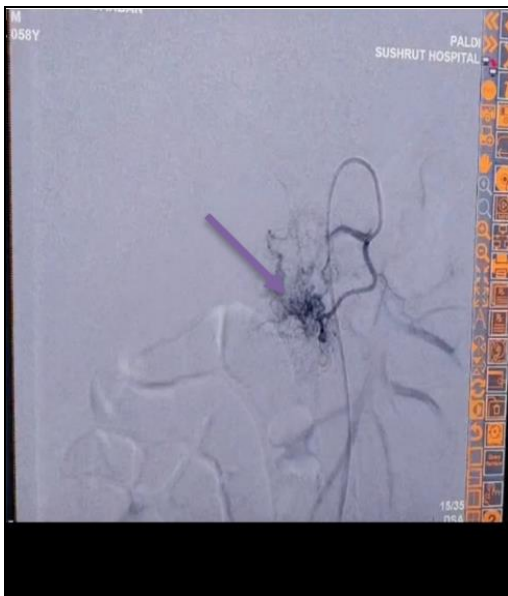
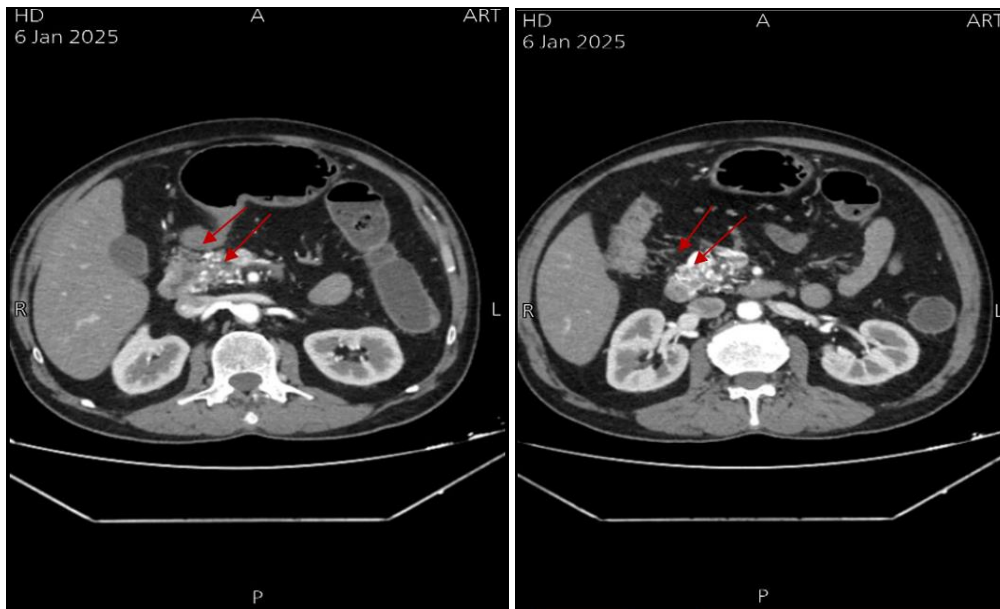


Image 3.

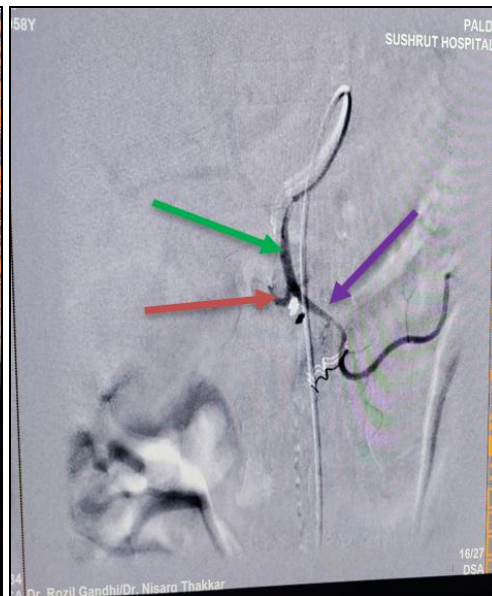


Image 4.

Image 3 (Pre-endovascular embolization DSA – digital subtraction angiography image - shows “blush” in the head region of pancreas – yellow arrow)

Image 4 (Post endovascular embolization with coiling DSA image– Gastroduodenal artery-- Green arrow, superior pancreaticoduodenal artery – orange arrow, Right gastroepiploic artery – purple arrow, no blush in the head of pancreas.)

Literature Review Purpose

A systematic search was performed across PubMed, Scopus, and Google Scholar for articles published between January 2000 and May 2025. Keywords included “pancreatic arteriovenous malformation,” “pancreatic AVM,” “vascular anomaly pancreas,” and “pancreatic vascular malformation,” paired with terms like “case report,” “management,” or “diagnosis.” Eligible studies were peer-reviewed, English-language articles or case reports focusing on human pancreatic AVM. Non-English studies without translations or those addressing non-pancreatic AVMs were excluded. Approximately 25 relevant studies were identified, with 12 selected for their clinical relevance and detailed reporting.

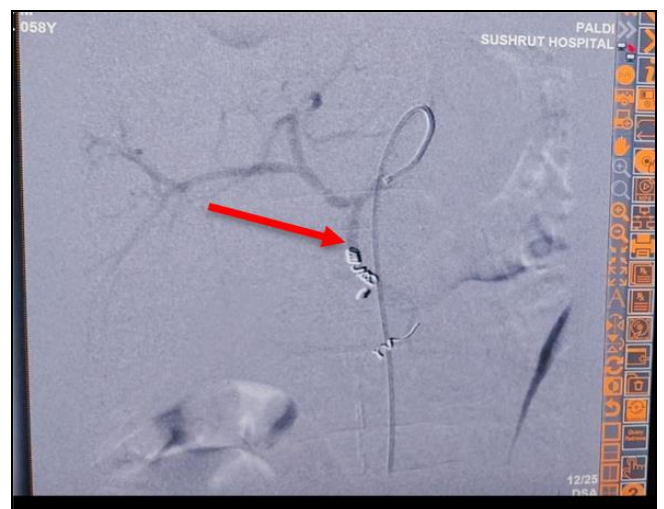

Image 5 [Post endovascular coiling – Gastroduodenal artery – red arrow]

Pancreatic AVM is a rare vascular disorder marked by aberrant connections between pancreatic arteries and veins, bypassing capillaries. Its prevalence is not well-

documented, but fewer than 100 cases have been reported since its initial recognition in the 1968^[4]. The condition typically affects adults, with a slight male predominance [male-to-female ratio ~1.4:1] and a median diagnostic age of around 48 years [range: 18–72 years]. Most pancreatic AVMs are congenital, stemming from embryologic vascular anomalies, though some are acquired due to trauma, inflammation, or neoplasia. Congenital cases may be linked to hereditary haemorrhagic telangiectasia [HHT] or Osler Weber Rendu syndrome, but isolated pancreatic involvement is uncommon. Pathologically, AVMs create high-flow shunts, resulting in venous hypertension, tissue ischemia, or haemorrhage. Lesions commonly occur in the pancreatic head [~55%], followed by the body or tail^[5], and may involve nearby structures, complicating treatment. The condition's scarcity and nonspecific symptoms often delay diagnosis.

Just like in literature we also found AVM in male patient with predominantly in pancreatic head region in our case.

The clinical presentation of pancreatic AVM is heterogeneous, contributing to diagnostic challenges. Abdominal pain is the most frequent symptom [65–75% of cases], followed by gastrointestinal bleeding [15–25%], presenting as melena, haematochezia, or anemia due to portal hypertension or mucosal involvement. Other manifestations include jaundice, acute pancreatitis, or incidental detection on imaging [~15%]. Rare but severe complications include lesion rupture, high-output cardiac failure, or portal vein thrombosis. Notably, some cases [~15%] are diagnosed only at autopsy, highlighting the condition's elusive nature.

The present case of a 57-year-old male with abdominal pain and melena aligns with the literature's focus on gastrointestinal bleeding as a hallmark of pancreatic AVM. However, the initial misdiagnosis as a pancreatic mass underscores diagnostic pitfalls less commonly reported. The successful use of TAE in this case supports its role as a first-line therapy, consistent with reported outcomes.

The rarity of pancreatic AVM precludes large-scale studies, leaving significant knowledge gaps. The natural history of asymptomatic lesions, optimal surveillance protocols, and factors predicting treatment failure remain unclear. The association with HHT in isolated cases warrants further genetic investigation, and novel therapies, such as anti-angiogenic agents, are still relatively underexplored.

Discussion

Arteriovenous malformations [AVMs] in the gastrointestinal [GI] tract are rare and can occur within the liver or in locations outside of it. In a review by Meyer *et al.*, 78% of GI AVMs were located in the cecum and right colon, followed by 10.5% in the jejunum, 5.5% in the ileum, 2.3% in the duodenum, 1.4% in the stomach, and 0.9% in both the rectum and pancreas^[6]

Extrahepatic AVMs involving arteriportal shunts—such as those between the accessory right hepatic artery, gastroduodenal artery, or superior mesenteric artery and the portal vein—have been documented. The majority [approximately 90%] of pancreatic AVMs are congenital, with 10–30% occurring in patients with Osler-Weber-Rendu syndrome^[7]. This condition is believed to result from a failure in the sphincter-like regulation at the arteriole-capillary junction, leading to unregulated arterial flow into the capillaries. Secondary pancreatic AVMs have been

linked to conditions such as trauma, neoplastic processes, chronic inflammation or as a complication of pancreatic transplantation which can create arteriovenous fistulas.

First described by Halpern *et al.* in 1968 in a patient with Osler-Weber-Rendu disease, pancreatic AVMs are extremely uncommon, with fewer than 80 cases reported to date. The actual incidence remains unclear, partly due to the asymptomatic nature of many cases. In a review of 42 cases, Nishiyama *et al.* found a mean diagnostic age of 48.8 years [ranging from seven months to 67 years], with a male predominance [78.6%] and congenital origin in 91% of cases. Half of these patients experienced significant GI bleeding^[7]. The AVM was most often found in the pancreatic head [56%], and 31% of cases also included extra pancreatic involvement. Surgical management varied and included resection [24 cases], pancreaticoduodenectomy^[10], distal pancreatectomy^[5], devascularization^[4], resection of adjacent organs^[5], and one total pancreatectomy.

Clinical presentation of GI AVMs ranges from asymptomatic cases to abdominal pain or bleeding. Haemorrhage typically results from variceal rupture due to portal hypertension or, less commonly, from erosion into the pancreatic duct or adjacent mucosa. Jaundice, though rare, can result from haemobilia if the AVM erodes into the bile ducts. The pancreatitis is thought to be caused by bleeding from the AVM into the pancreatic duct or by ischemia of the tissue due to vascular steal of the AVM^[9].

Imaging is critical for diagnosing pancreatic AVM, as clinical and laboratory findings lack specificity. Contrast-enhanced computed tomography [CT] is the primary modality, identifying hyper vascular lesions with early venous opacification and dilated vessels in 85–90% of cases. Magnetic resonance imaging [MRI] and endoscopic ultrasound [EUS] provide additional detail, particularly for small lesions. Angiography remains the gold standard, confirming the vascular architecture and guiding interventions. Misdiagnosis as pancreatic tumours [e.g., neuroendocrine tumours] is common, necessitating careful radiologic interpretation.

Diagnosis relies on imaging techniques such as ultrasound, CT, MRI, and angiography. On Doppler ultrasound, AVMs typically appear as hypoechoic lesions with a mosaic pattern and pulsatile flow in the portal vein. CT scans show early contrast enhancement in the portal vein, while MRI often reveals a signal void consistent with high-velocity blood flow. Angiography typically demonstrates enlarged, tortuous feeding vessels, a network of vascular channels within the pancreas, early portal vein filling, and transient pancreatic staining.

Doppler ultrasound serves as a non-invasive screening tool, while CT and MRI provide better anatomical detail. Angiography, despite overlapping features with conditions such as pancreatitis and hyper vascular tumours, remains essential for definitive diagnosis and treatment planning.

Treatment is guided by angiographic findings. Transcatheter arterial embolization can effectively manage bleeding and may be definitive or serve as a preoperative measure. However, recurrence is observed in roughly 37% of cases, often due to neovascularization^[8]. Nevertheless, embolization remains crucial, particularly for patients unfit for surgery.

Pancreatic AVMs tend to enlarge progressively, potentially causing portal hypertension—a complication that may persist even after complete AVM resection. For this reason,

early surgical intervention is often advised to prevent irreversible hemodynamic changes.

In the present case, the patient was taken up for endovascular embolization.

Conclusion

Pancreatic arteriovenous malformations [AVMs], though exceedingly rare, represent a clinically significant vascular anomaly due to their potential to cause severe complications, including gastrointestinal haemorrhage and portal hypertension. The nonspecific nature of early symptoms often delays diagnosis, underscoring the need for heightened clinical suspicion. Advanced imaging modalities—particularly colour Doppler ultrasonography, contrast-enhanced computed tomography, and angiography—are indispensable for accurate diagnosis and assessment of vascular dynamics. While therapeutic options include endovascular interventions, definitive management is most often achieved through surgical resection, especially when undertaken prior to the development of irreversible portal hypertensive changes. This review emphasizes the importance of early detection and timely intervention to mitigate morbidity and improve prognostic outcomes in affected individuals.

Conflict of Interest Statement

None.

References

1. Nikolaidou O, Xinou E, Papakotoulas P, Philippides A, Panagiotopoulou-Boukla D. Pancreatic arteriovenous malformation mimicking pancreatic neoplasm: a systematic multimodality diagnostic approach and treatment. *Radiol Case Rep*,2018;13:305–309.
2. Florence Nightingale – Demiroglu Science University. Florence Nightingale – Radiological findings of arteriovenous malformation in pancreatic head, 2021, 7(3). DOI: 10.5606/fng.btd.2021.3
3. Shearer DD, Demos TC, Sichlau MJ. Pancreatic arteriovenous malformation: a case report and literature review. *J Radiol Case Rep*,2011;5(8):8-13. doi: 10.3941/jrcr.v5i8.742. Epub 2011 Aug 1. PMID: 22470807; PMCID: PMC3303456.
4. Shin SH, Cho CK, Yu SY. Pancreatic arteriovenous malformation treated with transcatheter arterial embolization: Two case reports and review of literature. *World J Clin Cases*,2023;11(28):6920-6930. PMID: 37901023; DOI: 10.12998/wjcc.v11.i28.6920
5. Chou SC, Shyr YM, Wang SE. Pancreatic arteriovenous malformation. *J Gastrointest Surg*,2013;17(7):1240-6. doi: 10.1007/s11605-013-2217-2. Epub 2013 May 2. PMID: 23636883.
6. Deepak Gunjan, Vishal Sharma, Surinder S Rana, Deepak K Bhasin. Small bowel bleeding: a comprehensive review. *Gastroenterology Report*,2014;2(4):262–275. <https://doi.org/10.1093/gastro/gou025>
7. Makhoul F, Kaur P, Johnston TD, Jeon H, Gedaly R, Ranjan D. Arteriovenous malformation of the pancreas: A case report and review of literature. *Int J Angiol*,2008;17(4):211-3. doi: 10.1055/s-0031-1278312. PMID: 22477452; PMCID: PMC2728924.
8. Onozawa S, Miyauchi R, Takahashi M, Kuroki K. An Update of Treatment of Pancreatic Arteriovenous Malformations. *Interv Radiol [Higashimatsuyama]*,2023;8(2):49-55. doi:10.22575/interventionalradiology.2022-0037. PMID: 37485485; PMCID: PMC10359168.
9. Van Holsbeeck A, Dalle I, Geldof K, Verhaeghe L, Ramboer K. *Journal of Belgian Society of Radiology*,2015;99(1):37-41. DOI: 10.5334/jbr-btr.863.